

Interceptive treatment of tooth wear: a revised protocol for the full molding technique

Didier Dietschi, DMD, PhD, PD

Senior Lecturer, Department of Cariology and Endodontics, School of Dentistry,
University of Geneva, Switzerland

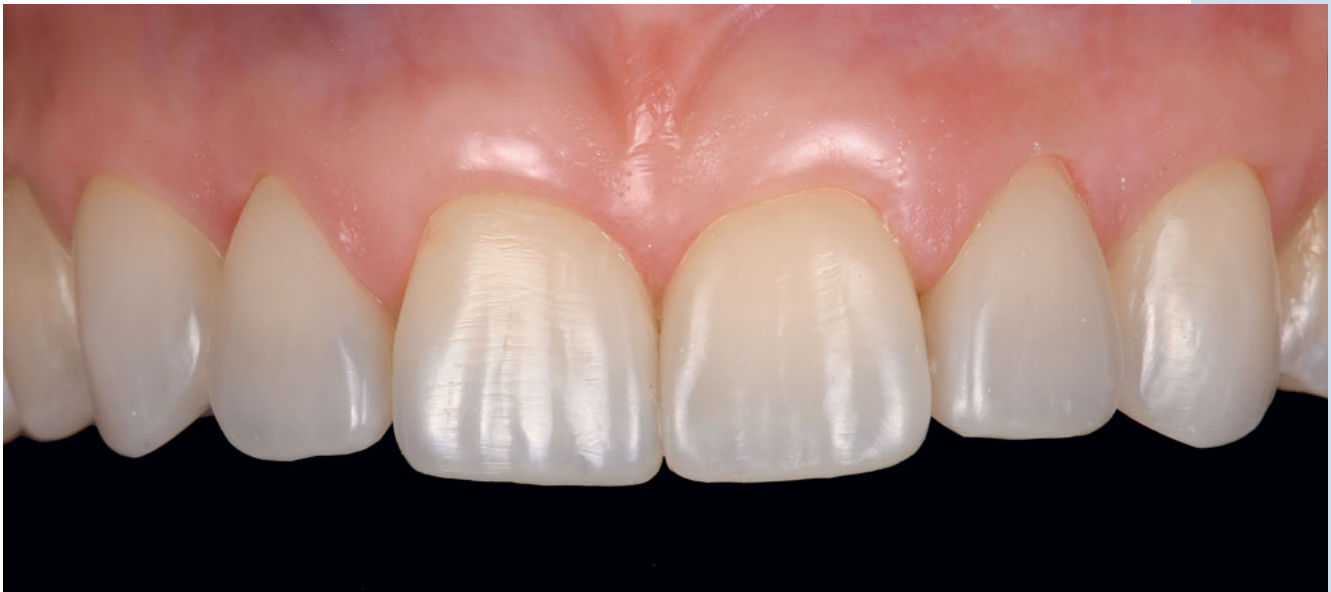Adjunct Professor, Department of Comprehensive Dentistry, Case Western Reserve
University, Cleveland, Ohio

Private Education Center & Clinic, The Geneva Smile Center, Geneva, Switzerland

Carlo Massimo Saratti, MD, DMD, Ms

Lecturer, Department of Cariology and Endodontics, School of Dentistry, University of
Geneva, Switzerland

The Geneva Smile Center Clinic, Geneva, Switzerland



Correspondence to: [Dr Didier Dietschi](#)

School of Dentistry, Faculty of Medicine, University of Geneva, 4 rue Lombard, 1205 Geneva, Switzerland;

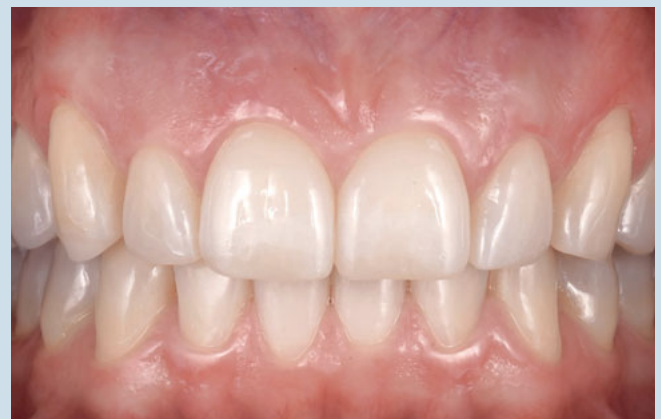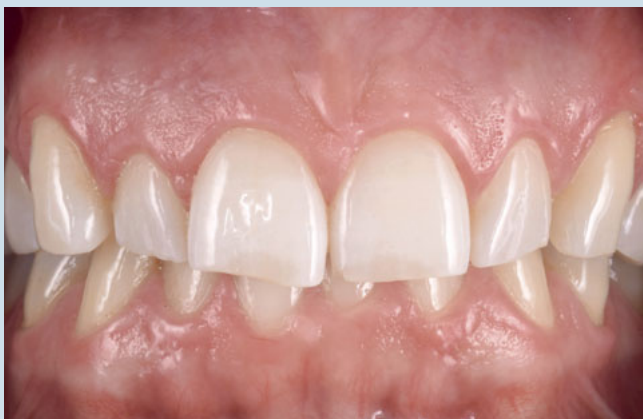Tel: +41 22 379 4177; Email: ddietschi@genevasmilecenter.ch

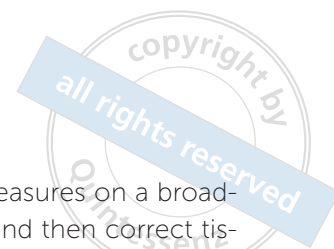Abstract

A modern approach to treating tooth wear aims to stop its progression at an early stage and, ideally, to install effective preventive measures or, in cases when it is already late, to intervene using an interceptive treatment approach. It is important to avoid the need for a full prosthetic treatment that implies additional tooth substance removal, with potential biologic complications. As signs of tooth wear often appear in young individuals, an interceptive treatment has the great potential of stabilizing tooth wear progression early using a no-prep approach and composite resins. The additional benefit of this treatment approach is its affordability and maintainability in the light of tooth wear being, usually, a lifelong pathology. Among the various options for restoring tooth wear lesions with

composite resins, interest has lately been increasing for molding techniques (single or full) due to their efficiency and simplicity. This article describes modifications of the basic full molding technique to alleviate most of the known shortcomings of this method; namely, the index deformation, the time-consuming removal of excesses in the proximal and contact areas, and the possible insufficient precision in the molding of the occlusal anatomy. The 1- and 3-year follow-ups of both cases presented here confirmed the functional and esthetic quality of the results obtained with this technique. A kinesiographic and 3D superimposition of the posttreatment and 1-year results of one case provided additional perspectives on this treatment method.

(*Int J Esthet Dent* 2020;15:264–286)





Introduction

Attrition and erosion are two common conditions considered to be an increasing phenomenon in all age groups,¹⁻⁵ representing a challenge on both the preventive and restorative levels. As broad symptoms of tooth wear have also increased in young people, a lifelong approach becomes essential, first to slow down the progress of hard tissue loss and then to make treatment and retreatment affordable in the long term. This consideration relates not only to the financial impact but also the biomechanical implications of a potentially lifelong pathology. Conjointly, the progress of prevention and the subsequent decline of carious and periodontal pathologies has made it possible for many people to retain most of their natural dentition, indirectly increasing the exposure of their teeth to wear.

Moreover, tooth wear results from various conditions often acting in a detrimental synergy, including erosive pathologies, parafunctions, and wrong functional habits. Erosion involves unbalanced dietary habits with a high consumption of acidic food or beverages (such as fruit, carbonated drinks, fruit juices, and vinegar) as well as abnormal intrinsic acid production (acid reflux and hiatal hernia), the worst condition being bulimia nervosa.⁶⁻⁸ Insufficient salivary flow rate or buffer capacity, and, in general, salivary composition changes induced by various diseases, medications, and aging are other etiological co-factors. As regards abrasion, awake and sleep bruxism are two different forms of parafunctional activities that can severely affect tooth integrity.^{9,10} As previously mentioned, an important consideration is that many patients affected by tooth wear present combined etiologies, which complicates diagnosis and requires a multifactorial, preventive, and restorative treatment approach.^{11,12} Installing preven-

tive and interceptive measures on a broader level to slow down and then correct tissue and restoration destruction has become a paramount challenge of modern dentistry. It is unfortunate to observe so many severe tooth wear cases that were neither diagnosed nor treated early enough, mainly due to the lack of interceptive treatment awareness by both professionals and patients.

When dealing with intermediate tooth wear stages (slight to moderate erosion and/or abrasion), conservative clinical measures can be applied such as various forms of direct or indirect partially bonded restorations. The aim of this article is therefore to present a sound clinical concept for addressing various forms of early restorative intervention using a revised protocol for chairside molding of direct composites.

Overall treatment approach and options

The most widely used restorative options include direct partial composite restorations and indirect partial composite or ceramic restorations. The use of indirect full-ceramic restorations is typically limited to the replacement of existing crowns or the treatment of severely weakened or discolored non-vital teeth. As preventive and interceptive approaches progressively receive broader acceptance for the prevention of tooth wear progression, the direct composite approach is logically the main treatment option for the future due to its simplicity and low cost. The strength of evidence is growing with regard to composite resins used successfully to restore both anterior and posterior worn dentitions.^{11,12} Over short-, medium-, and even long-term observation periods, minor failures such as wear, marginal discoloration, and chipping are the most frequent complications, requiring only



repair in the majority of cases.^{13,14} In a 10-year study comparing the treatment outcome of direct composites and porcelain-fused-to-metal crowns, the prosthetic option showed slightly fewer failures, even though it was more severe in nature (endodontic complication) and sometimes even untreatable (fractures leading to extraction).¹⁵

A modern vision for tooth wear treatment is primarily to stop its progression before classical prosthetic rehabilitation becomes needed, which then involves a substantial removal of additional tooth substance. Actually, due to possible biological complications of more invasive procedures,¹⁵ and despite the pleasing esthetic outcome and usually satisfactory strength of extensive ceramic restorations, their rather 'inadequate' biomechanical rationale contraindicates their use in moderate tooth wear cases and as a systematic treatment approach.

Nowadays, apart from the selection of a restorative option, treating tooth wear involves four basic steps:

1. A comprehensive etiological clinical investigation aimed at identifying all local risk factors (functional and chemical) as well as other general medical cofactors.
2. Treatment planning, including proper functional and esthetic schemes defining a new smile line, and improved anterior and posterior tooth anatomy and function. This step can be performed using either classical analog or modern digital wax-up techniques.
3. Transfer to the mouth of the new esthetic and functional schemes with only no-prep restorations, using direct and/or indirect adhesive techniques.
4. A long-term patient monitoring and maintenance program based on identified risk factors, very often including a protective night guard. In the short to

medium term, repolishing or repair is to be considered at regular intervals (composite option mainly), and, potentially, also restoration replacement for both composite and ceramic restorations for the medium to long term.

While the conceptual and practical advantages of direct no-prep composite restorations were outlined and recognized in numerous clinical reports as early as 1992,^{16,17} the freehand approach was constrained by its inherent technical 'difficulty.' Some simplification and alternatives to the direct bonding technique were then expected, and the idea emerged of molding composite using a translucent index (produced from a wax-up).¹⁸⁻²⁰ However, some technical issues remained linked to full molding techniques such as the removal of interproximal, facial, and lingual excesses after pressing the composite simultaneously over several teeth, and the time involved in molding restorations tooth by tooth, with some possible index deformation. To achieve a reliable transfer of the wax-up to the mouth with a highly filled composite within an acceptable time-frame, key steps are required to improve the traditional protocols. These steps are presented below.

Modified full molding technique – a new protocol

A first important condition applying to all direct techniques (from freehand to the full molding approach) is to have occlusal and proximal references to guide composite sculpting or molding, ensuring a more precise functional and anatomical outcome. This being granted, the overall steps to be considered additionally or instead of those applied with a basic molding technique (clear index with no other specific feature) are (Fig 1):

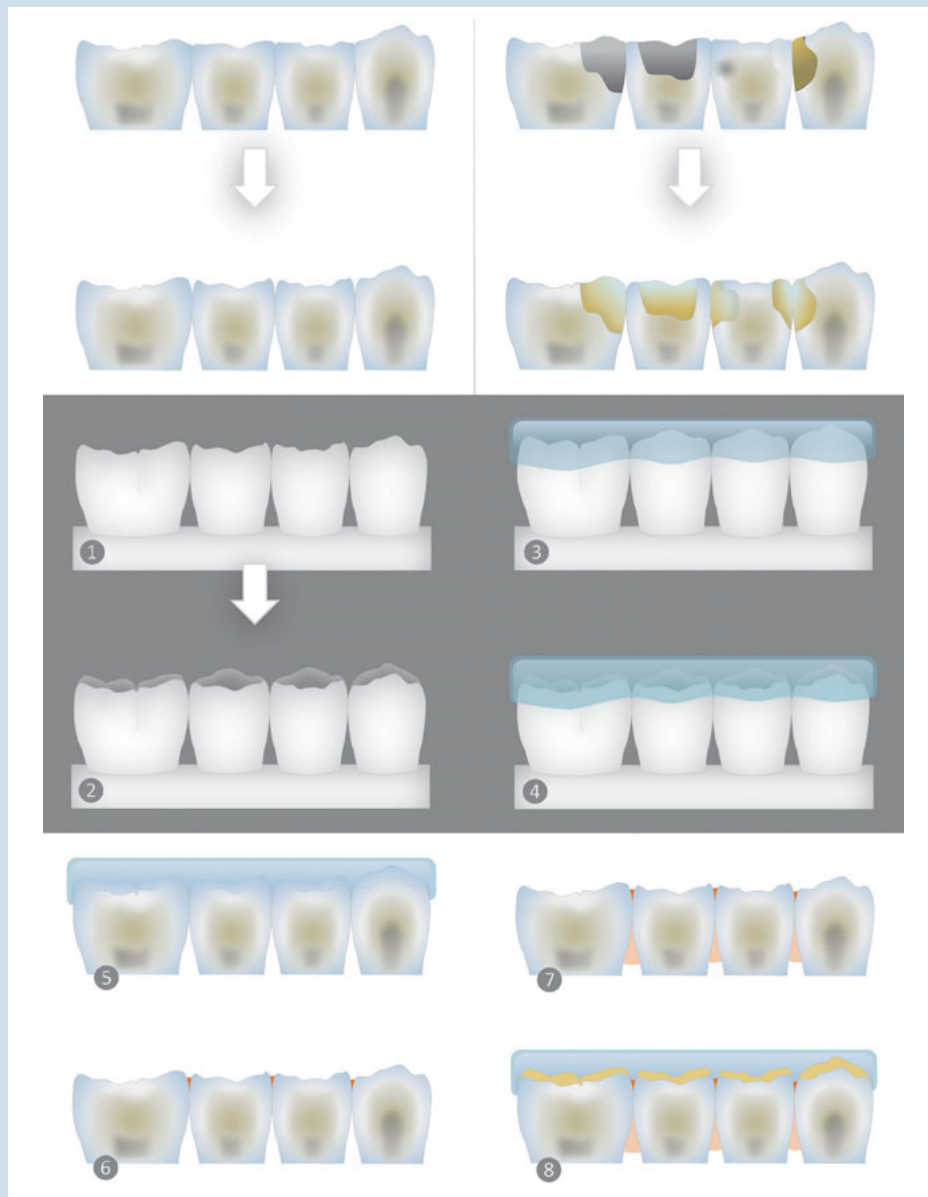


Fig 1 Workflow of the revised full molding technique for the interceptive treatment of tooth wear. Section 1 (white frame) – Clinical scenarios: (left) These images illustrate the need to open the occlusal embrasures using ultrathin discs to help proper isolation of this area and simultaneously provide stabilization of the tray/index during molding (vertical stop); (right) These images demonstrate the need to restore carious lesions and replace decayed or metallic restorations prior to the molding process. In this case, the restorations are made at the preexisting vertical dimension of occlusion (VDO), while the occlusal embrasures should also be opened, if needed. Section 2 (gray frame) – Basic laboratory sequence: Study casts produced from both the clinical scenarios (with and without Class I/II restorations). (1) An improved anatomy and function is determined with a wax-up at a new, increased VDO; (2) Then, the model with the wax-up is duplicated for the fabrication of a thick translucent tray (3). This tray is finally relined with a clear, low-viscosity silicone material on the initial model to obtain an accurate wax-up replication and molding outcome (4). Section 3 (white frame) – Basic restorative sequence: The tray is tried intraorally to ensure proper positioning and the existence of composite extrusion zones that will facilitate the molding process (5). A small quantity of isolation material (ie, Rubber Sep; Kerr) is placed in the occlusal embrasure to prevent composite penetration inside the interdental contact (6). For cases with open cervical embrasures, those areas can also be filled up with Teflon tape to prevent possible composite excess there too (7). The final step involves composite molding to restore lost tooth structure (8).



1. Having a good anatomical and functional wax-up, managing mesial and distal stops to stabilize the future molding tray (usually one or two incisors and the distal occlusal surfaces of the second molars, if needed).
2. Use of a heat-formed, hard, thick, plastic tray (≥ 2 mm) to prevent index deformation. The tray has to be precisely cut to facilitate the full removal of the composite excesses (about 1.5 to 2.0 mm of further worn surfaces and/or the wax-up facial and lingual extension).
3. The tray is relined with clear silicone on the wax-up for optimal detail reproduction.
4. Slight opening of occlusal embrasures (if non-existent) to obtain precise and accessible margins of molded restorations and create space for the application of an isolation material.
5. Isolation of occlusal and cervical embrasures to limit composite penetration in those critical zones.
6. Precise etching and dental bonding agent application around the worn surfaces (maximum 1 to 2 mm further in these areas) to limit the adhesion of composite excesses and facilitate their removal after composite light curing.

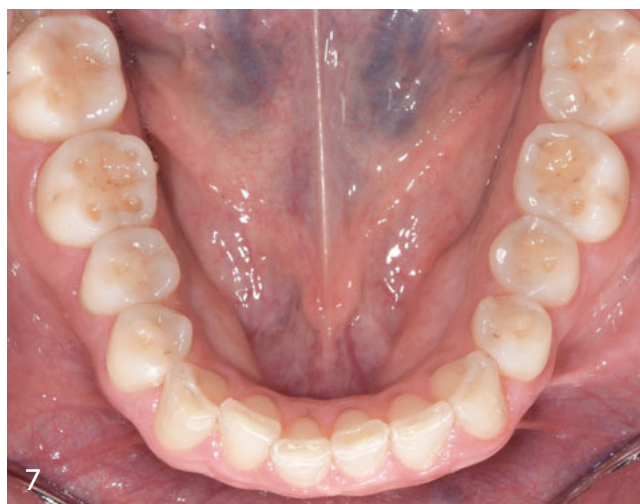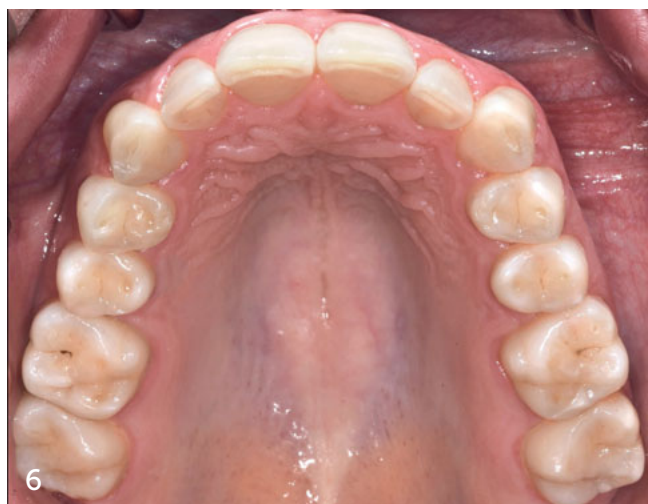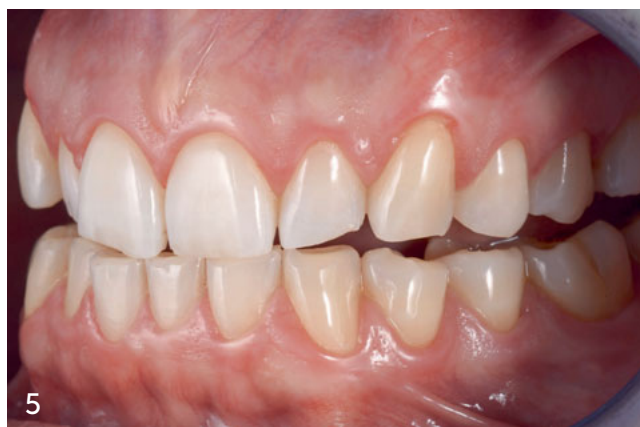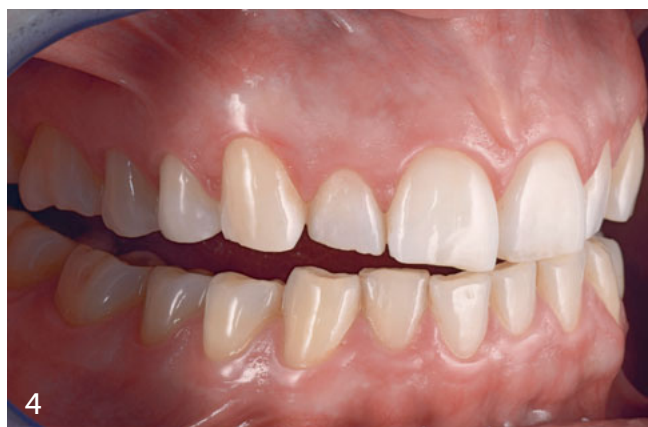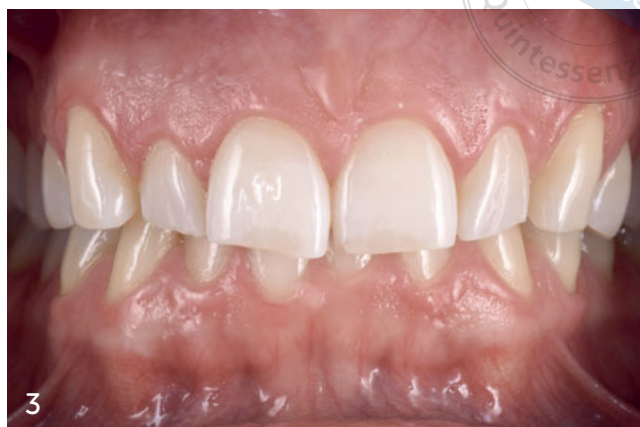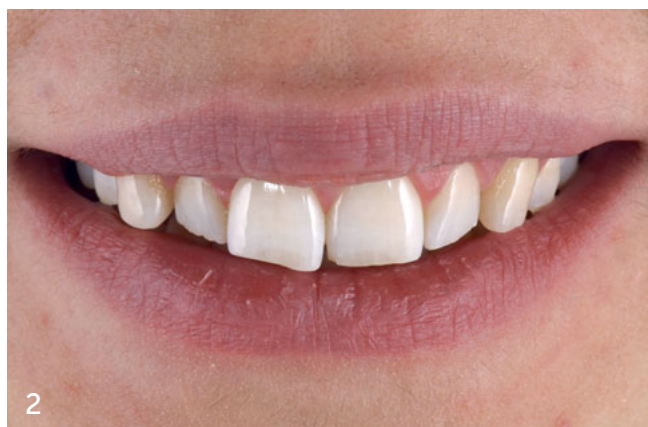The above steps limit time-consuming finishing procedures or delicate occlusal adjustments that formerly impacted treatment acceptance by both the patient and the dentist. Another imperative requirement is the need for proper cast mounting (analog or digital) preceding the production of an optimal wax-up with ideal anatomy and function, which is instrumental to a successful and reliable protocol outcome. The present case presentation illustrates the clinical application of this revised protocol.

Case presentation

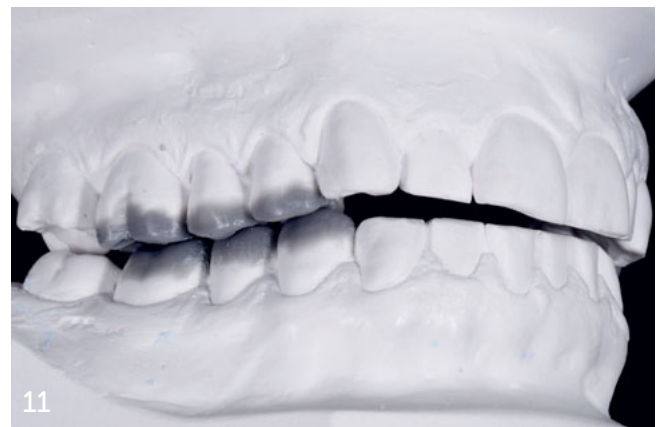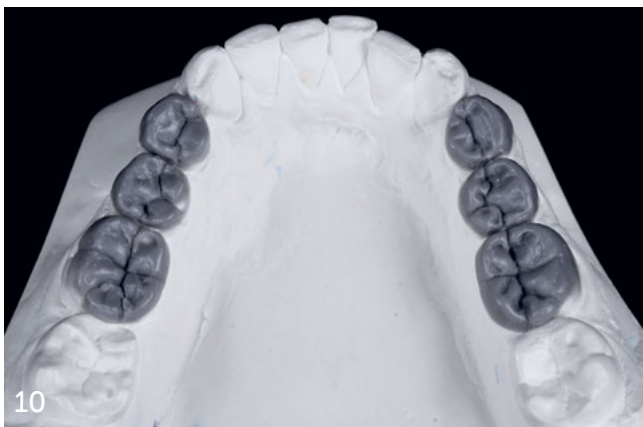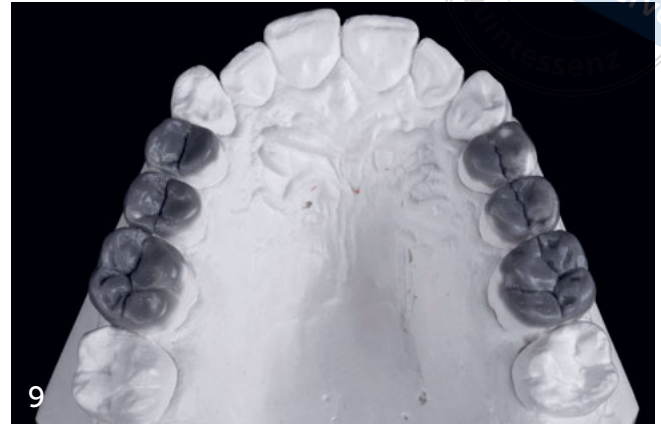
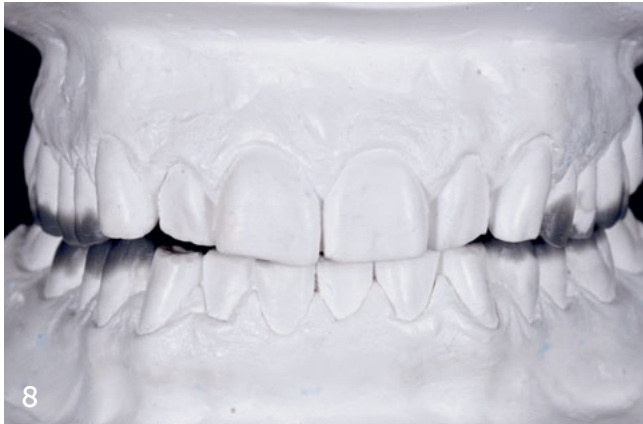A 35-year-old female patient presented for a counseling consultation to resolve esthetic and functional concerns. She was made aware of a progressive tooth wear problem by the referring dentist (Figs 2 to 7). The patient falls within the 60% of patients who are mainly mindful of the esthetic impact of tooth wear on their dental situation while not reporting substantial dentin hypersensitivity, pain or functional problems.²¹ Clinical and functional examinations otherwise revealed a Class II division 1 occlusion, and a moderate amount of generalized tooth wear in both the anterior and posterior segments. The observed wear pattern suggested bruxism to be a main contributing factor, with dental erosion as a secondary factor. Although medical and diet anamnesis did not reveal anything particular regarding the latter contributing factor, the patient was informed about the usual preventive measures (controlled consumption of acidic food and beverages) to limit further possible erosion. A more detailed functional and occlusal evaluation was also performed on mounted study casts (Fig 8). The possibility of correcting the misalignment and visible shortening of the patient's anterior teeth as well as the irregular smile line (even though this was not the patient's first complaint) was also considered.

The suggested treatment plan involved the following steps:

1. Restore worn posterior teeth using a no-prep approach with a direct full molding technique, as described above.
2. Free the functional anterior teeth to allow for their orthodontic realignment, and restore proper anterior guidance using clear aligners (Invisalign).
3. Complete the treatment with no-prep anterior direct composite restorations to optimize esthetics and function.



Figs 2 to 7 Preoperative status of a 35-year-old female patient referred for an esthetic and functional correction of moderate tooth wear. Note the irregular smile line (Figs 2 and 3) with the loss of canine guidance (Figs 4 and 5) due to latero-protrusive parafunctions. Occlusal views also show signs of erosion, as suggested by the typical hollowed lesions, mainly visible in the mandibular molars; flattening of cusps both in the maxillary and mandibular posterior teeth is also characteristic of the observed parafunctional movements.



Figs 8 to 11 The first laboratory diagnostic step involved a VDO increase and the replacement of worn occlusal tooth structures. The lateral view (Fig 11) shows the anterior space to be created for achieving the desired esthetic and functional objectives (improved smile line, alignment of anterior teeth, improved anterior function and guidance with more adequate overjet and overbite).

The proposed treatment first had to be simulated and confirmed by a full posterior wax-up (Figs 8 to 11), produced on mounted stone casts. To this end, a 4 mm vertical dimension of occlusion (VDO) increase at the incisal guide of the articulator was considered suitable to restore the posterior tooth anatomy, improve function, and provide enough space for the restorative material, following a no-prep protocol. Such an increase is considered safe and not prone to creating any functional disruption or temporomandibular disorders.^{22,23} The new VDO defined by the wax-up had to be confirmed with a setup of the maxillary and mandibular anterior teeth to ensure that it

was adequate for the planned orthodontic corrections (Fig 12).

After completing the wax-up, a 2-mm-thick hard tray (Erkodur; Erkodent) was produced by heat forming on the duplicate of the mandible (Figs 13 and 14). The tray was cut into two parts (left and right, sectioned at the midline line, and then relined with a clear silicone (Memosil 2; Heraeus) directly on the wax-up to capture all the anatomical details (Figs 15 and 16). The tray can have mesial and distal stabilization points; usually, part of (or the entire) occlusal surface of the second molar and anterior teeth also serve this purpose. The molding technique was performed on the full arch, in one session.

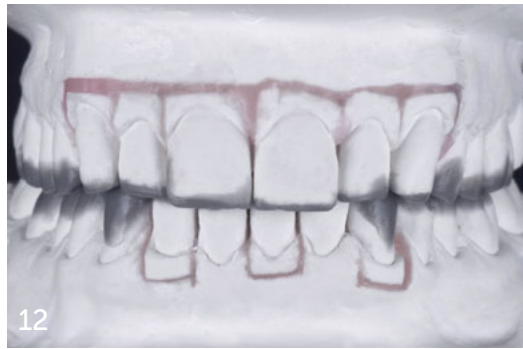
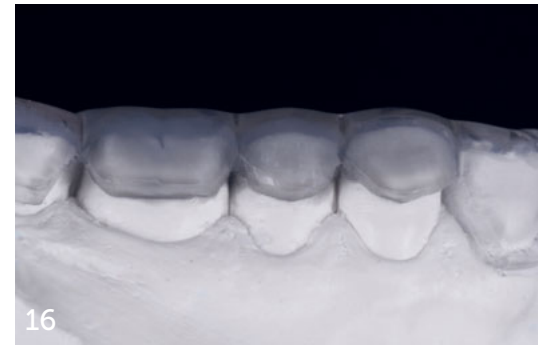
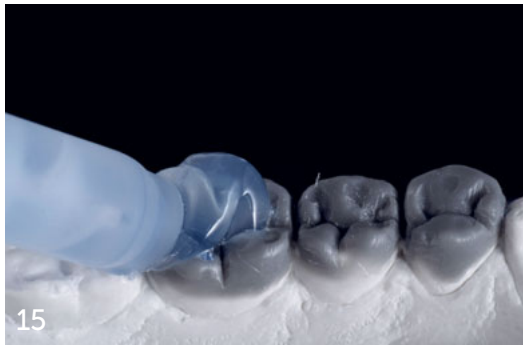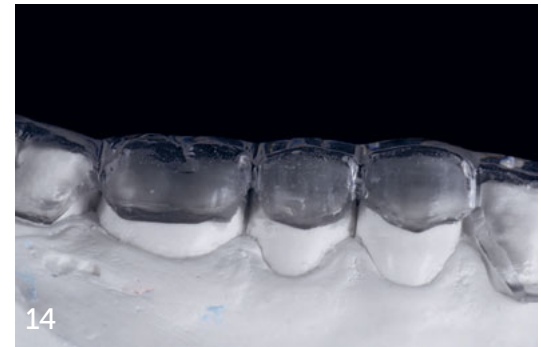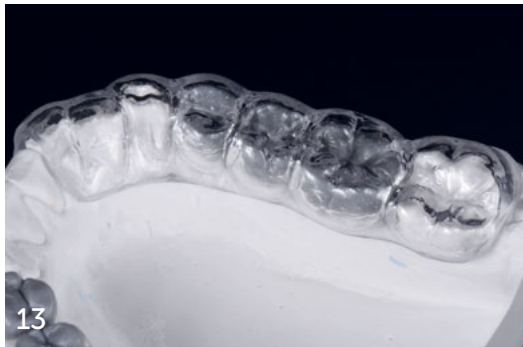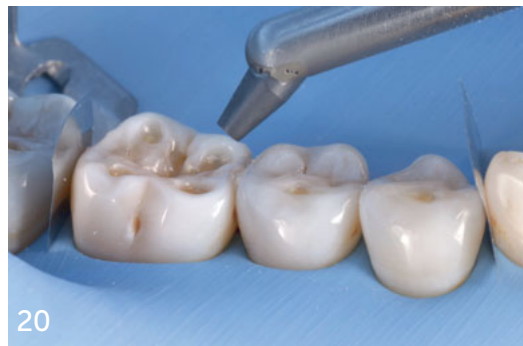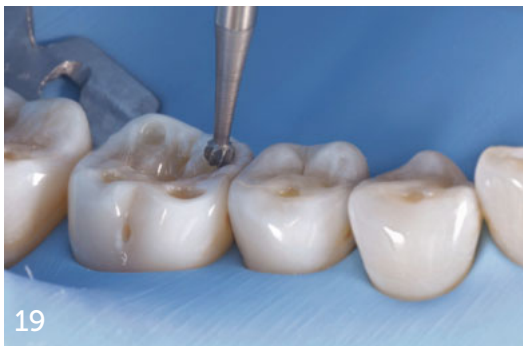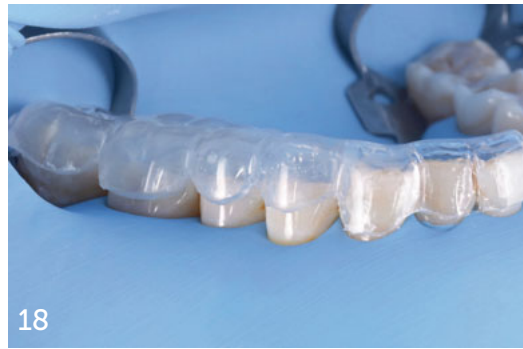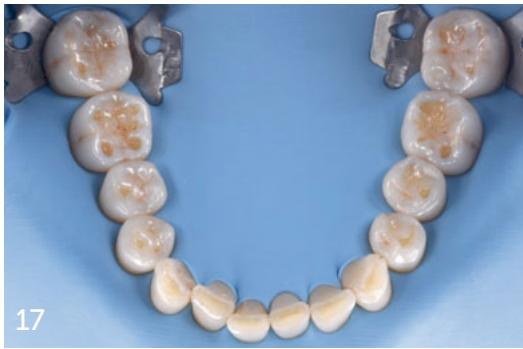Fig 12 The second laboratory diagnostic step demonstrated that the planned VDO increase would allow for the realignment of both the maxillary and mandibular anterior teeth with the Invisalign system. The treatment would then include two steps: first the VDO increase, and then the orthodontic correction of the anterior areas.



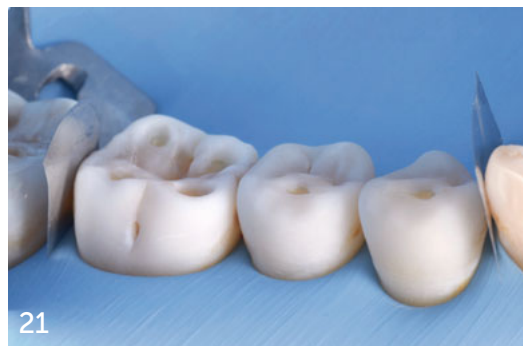Figs 13 to 16 A heat-formed, thick, translucent tray was fabricated on a wax-up duplicate and then relined directly on the wax-up using a low-viscosity, clear, silicone material.

What follows is a step-by-step documentation of the work on quadrant 4: The full inferior arch was initially isolated with rubber dam (Fig 17). Before starting the restorative procedure, the silicone key was tested to check the precision and fit (Fig 18). The tooth 'preparation' involved only a slight roughening of the dentin lesions with a round carbide (steel) bur (Fig 19), followed by full sandblasting of the occlusal surfaces (Figs 20 and 21). A three-step etch-and-rinse

adhesive system (OptiBond FL; Kerr) (Figs 22 and 23) was applied after selective acid etching using 37% phosphoric acid (Ultra-Etch; Ultradent) for 30 s and 10 s on the enamel and dentin, respectively. The adhesive system was subsequently polymerized for 20 s. A small amount of isolation material was also placed in the occlusal and proximal embrasures (Rubber Sep; Kerr) to avoid penetration of the composite in the tricky (Fig 24). Then, the heated homogenous



Figs 17 to 21 The preparation for molding involved a full-arch isolation with rubber dam (Fig 17). After the trial of the molding tray/index (Fig 18), the exposed dentin was roughened with burs before a full sandblasting of the occlusal surfaces to be restored (25- to 50- μ m Al_2O_3).



composite (inspiro, Skin White; Edelweiss DR) was placed into the tray, applied over the teeth (Fig 25), and pressed with gentle pressure until achieving its final position, as checked on mesial/stops (the tray should fit closely with the non-waxed surfaces or teeth). Due to the appropriate tray design, composite excesses could easily be removed on the facial, lingual, and interproximal surfaces (Fig 26). Light curing was then performed occlusally for 20 s per tooth

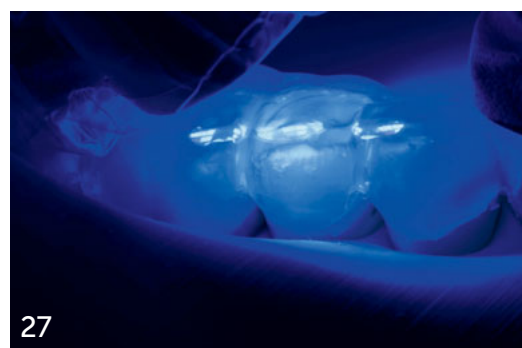
with the tray in place (Fig 27). After tray removal (Fig 28), 20 s of light curing was repeated on each surface. The overall process was then also completed on quadrant 3. Removal of small excesses and finishing followed, performed with a No. 12 blade, discs, and fine diamond burs (flame and football shapes, 40 μ m). Polishing with rubber points (Identoflex Minipoint; Kerr) and brushes (Occlubrush; Kerr) completed the process and provided a smooth composite surface

Figs 22 and 23

A classical three-step etch-and-rinse adhesive system was used to achieve maximum stability of the adhesive interface.

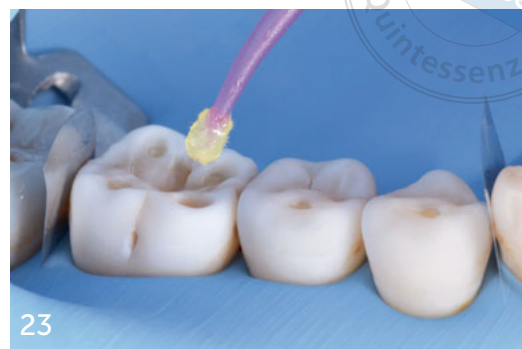
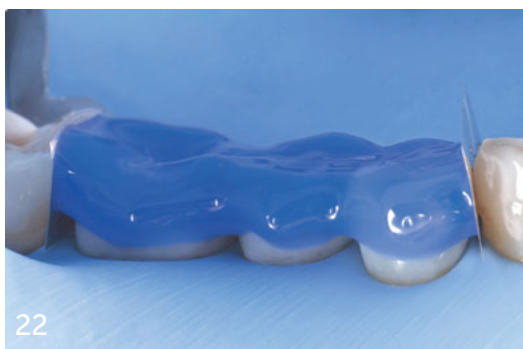
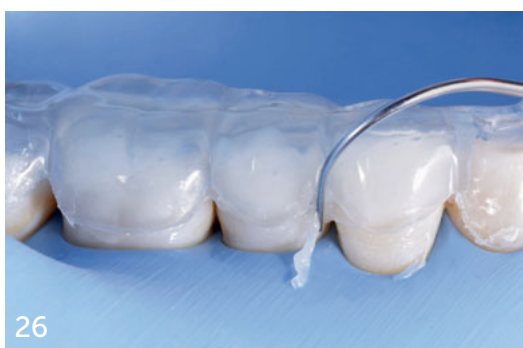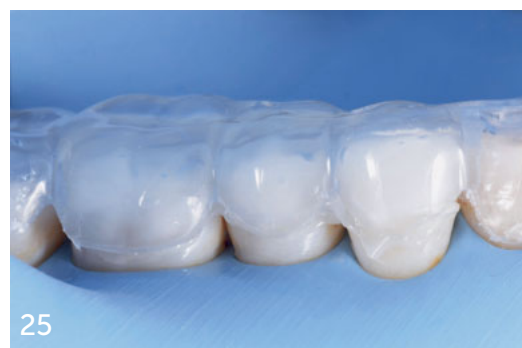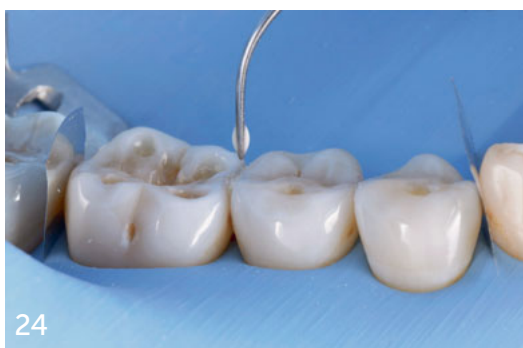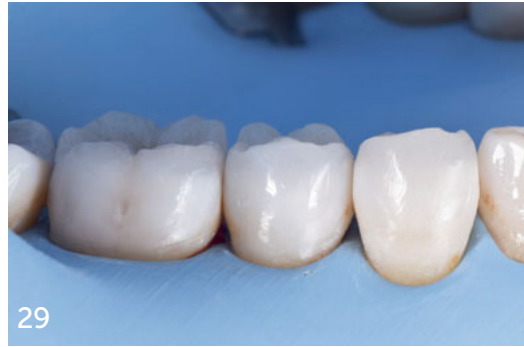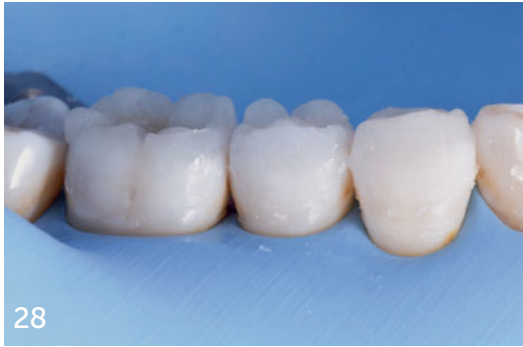Fig 24 Isolation of the occlusal embrasures was performed with a layer-forming separation medium. The latex-based material prevents the penetration of composite inside the contact area, which formerly proved to be one of the main shortcomings of the full molding approach.



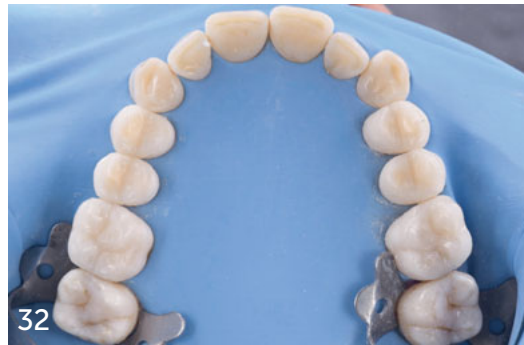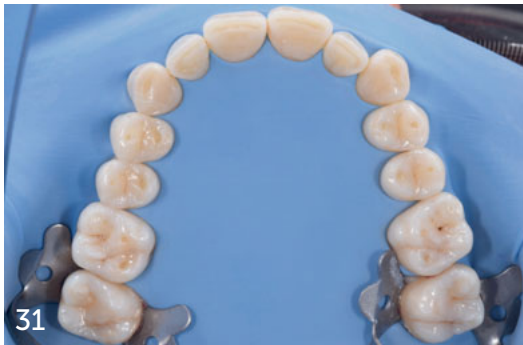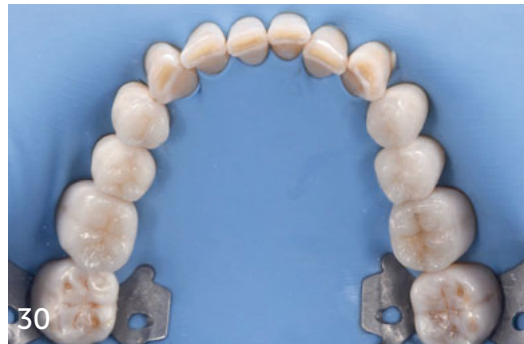Figs 25 to 27 The composite was then molded at once on all the left and then right posterior teeth, respectively. The composite excesses could be removed before polymerization thanks to a proper tray design; actually, the tray embrasures were sufficiently opened to give access to all critical areas.

and transition with underlying tooth structure (Figs 29 and 30). The full process was repeated on each maxillary quadrant sextant (Figs 31 and 32). After rubber dam removal and completion of the molding process for both sides on the mandible, a final occlusal check was performed. Additional checks and occlusal adjustments were also done in the course of the next treatment steps.

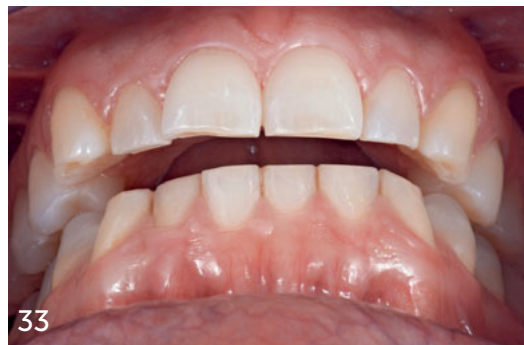The interocclusal space created in the anterior area allowed for the orthodontic alignment to take place immediately after performing the VDO increase. The planned esthetic and functional project included the realignment of the maxillary and mandibular anterior teeth as well as the creation of an adequate space to restore them to a more ideal length and anatomy, while providing an optimal overjet and overbite (Fig 33).



Figs 28 to 30 As only limited composite excesses resulted from the molding process (Fig 28), a swift finishing and polishing could be performed. Note the detailed replication of the wax-up anatomy. Only an enamel shade of restorative composite was used (shade Skin White, inspiro).



Figs 31 to 33 The same procedures were repeated for the maxillary arch, until the planned new VDO was reached to create a proper anterior space for the alignment of the anterior teeth as well as the future restorations.



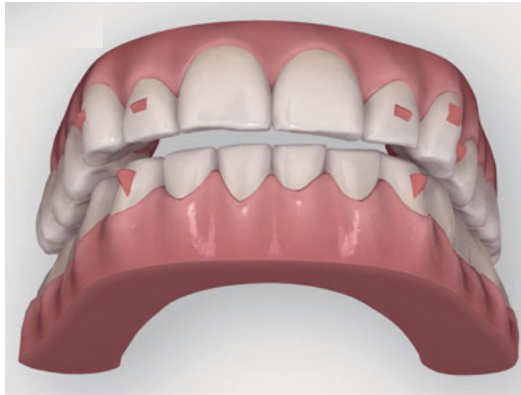
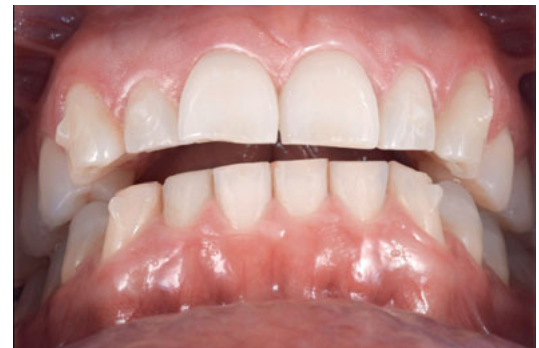
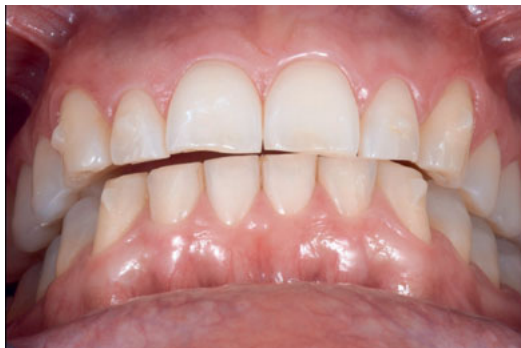
Fig 34 Planned post-Invisalign situation as defined by the Clean Check.

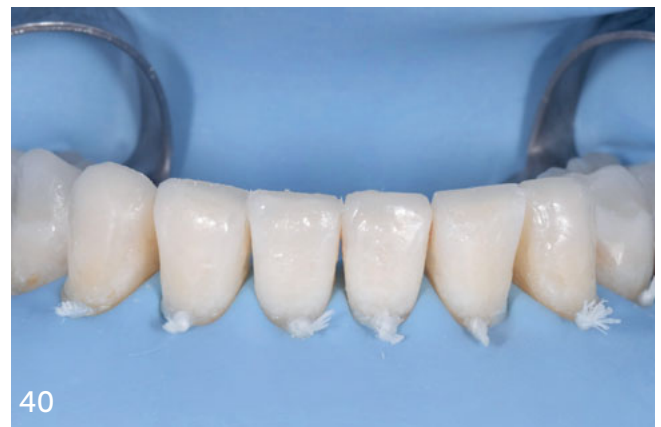
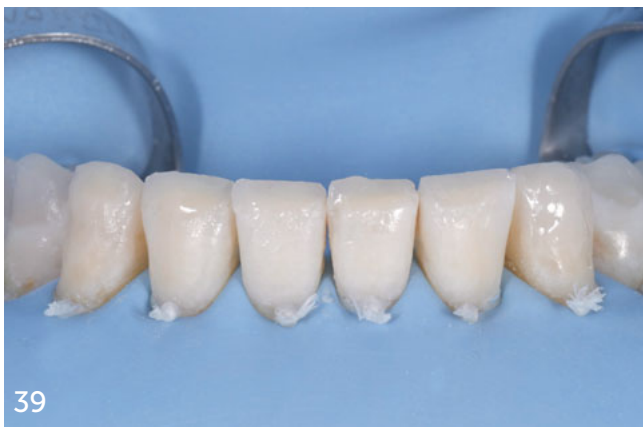
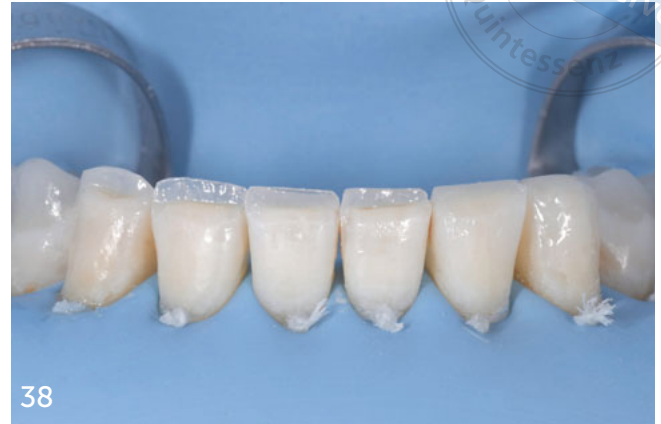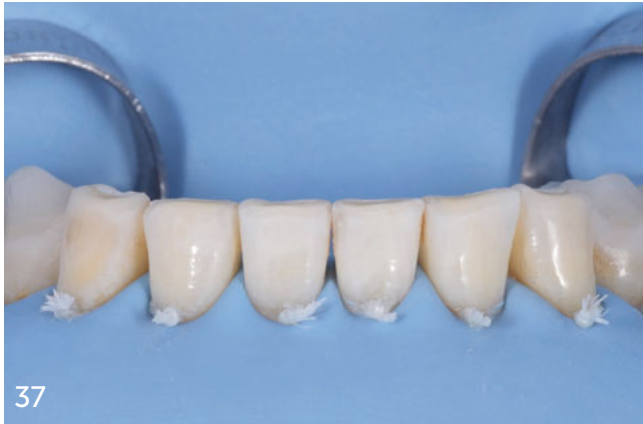Figs 35 and 36 Intermediate situation after the first 3-month treatment period (Fig 35), and final result of the Invisalign treatment providing the needed interocclusal space and relationship (Fig 36).

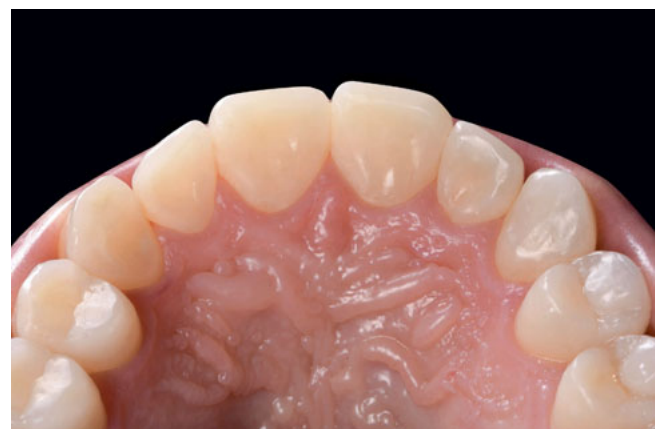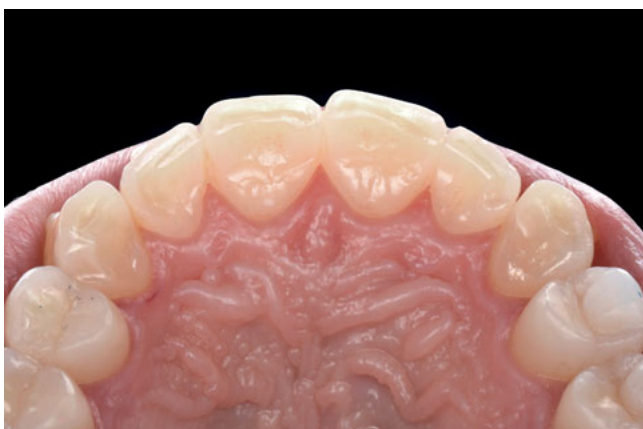The orthodontic correction provided an anterior relationship (overjet–overbite) that was even more convenient than the one initially planned (from the Clean Check) (Figs 34 to 36). It is assumed that this outcome resulted from an anterior shifting of the jaw position following the VDO augmentation, in addition to a significant reduction of the preexisting deep bite. When the new anterior tooth position was achieved, direct composite restorations were performed to restore the incisal edge of the inferior anterior sextant using a freehand approach, taking as reference the length of teeth 34 and 44 (Figs 37 to 40); although not used here, such a buildup could also have been performed with an index made from a second partial wax-

up. The buildups comprised a first lingual/palatal enamel layer (inspiro, Skin White) (Fig 38), the dentin core (inspiro Bi3) at the tooth edge (Fig 39), and a last labio-proximal enamel layer using the same mass as for the lingual/palatal increments (Fig 40). The same additive approach was performed to restore the palatal face of the maxillary anterior sextant (Figs 41 and 42). The final result of the rehabilitation is shown in Figures 43 to 52. Maxillary and mandibular night guards (Erkodur plates) were provided to help prevent orthodontic relapse and further natural tooth wear. These were to be worn daily and alternatively in both arches (Fig 53).

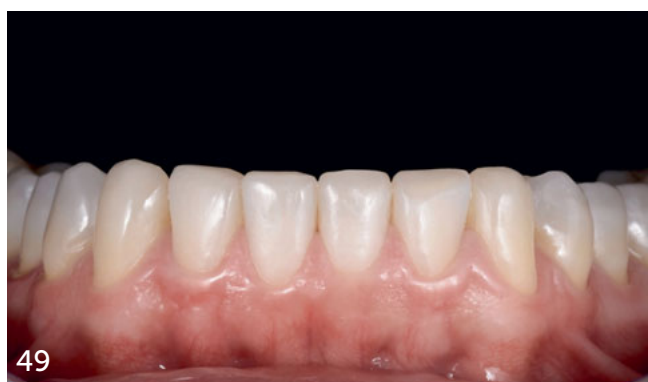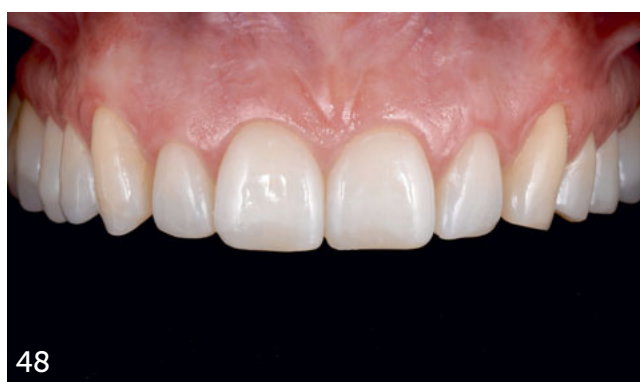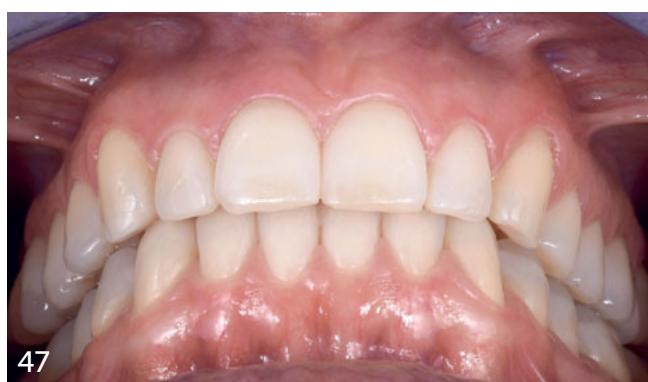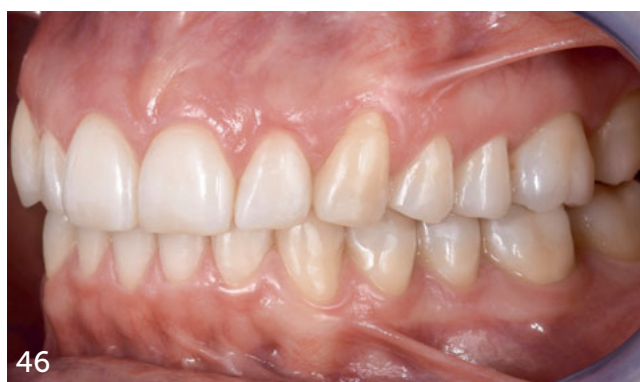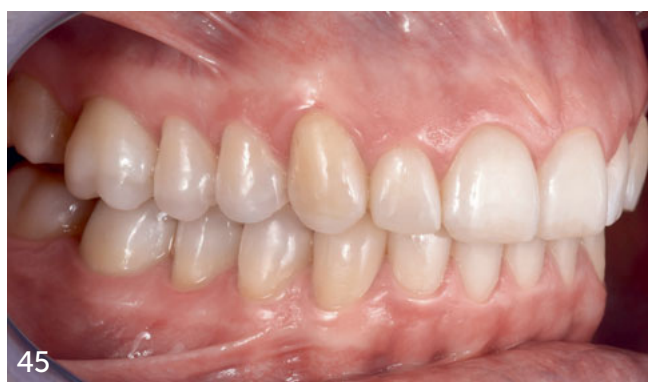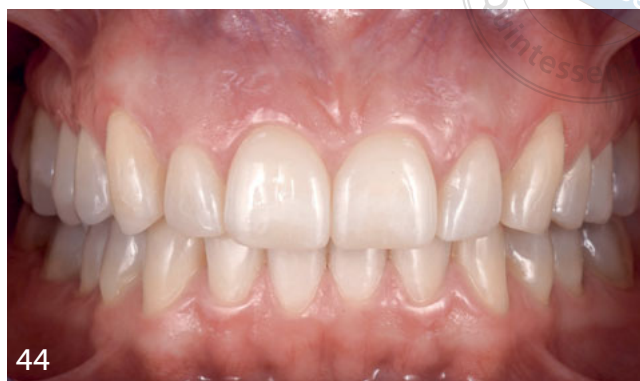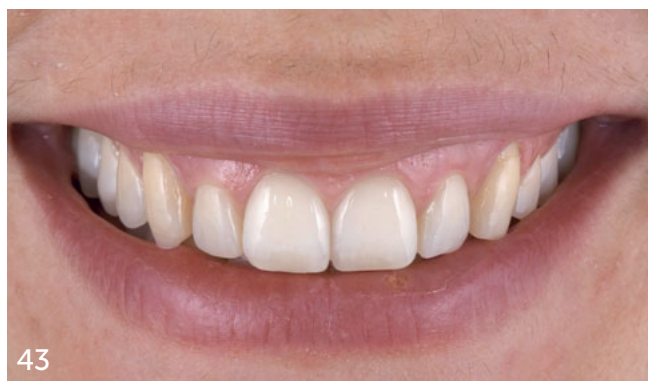The 1-year follow-up showed a stable status of the rehabilitation (Figs 54 to 58).



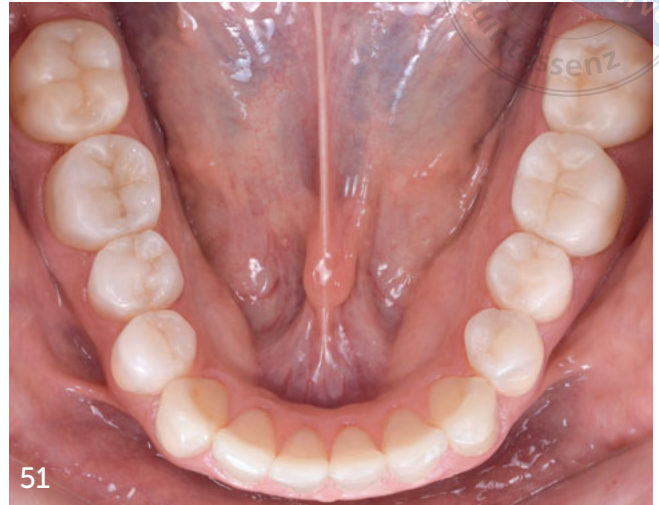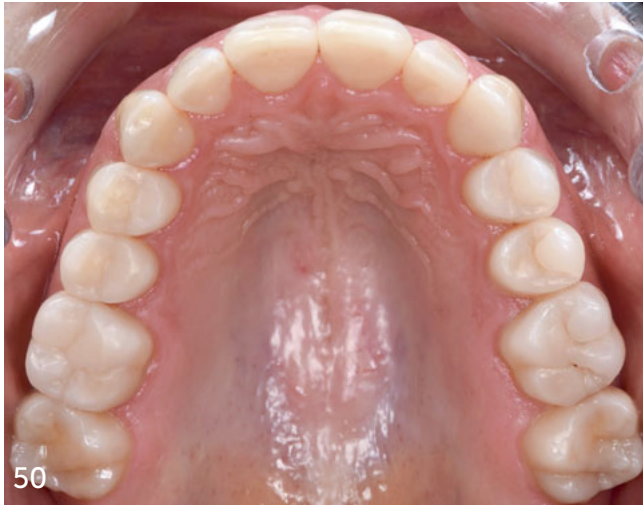Figs 37 to 40 The direct reconstruction of the mandibular anterior incisal edges was performed with composite following a bilaminar technique (dentin and enamel restorative masses – inspiro system).



Figs 41 and 42 Some form and functional corrections were also performed on the maxillary palatal surfaces and incisal edges, using the same composite material and bilaminar layering protocol.



Figs 43 to 49 Posttreatment views showing good tooth alignment, an improved smile line, and proper anterior and lateral occlusal relationships.

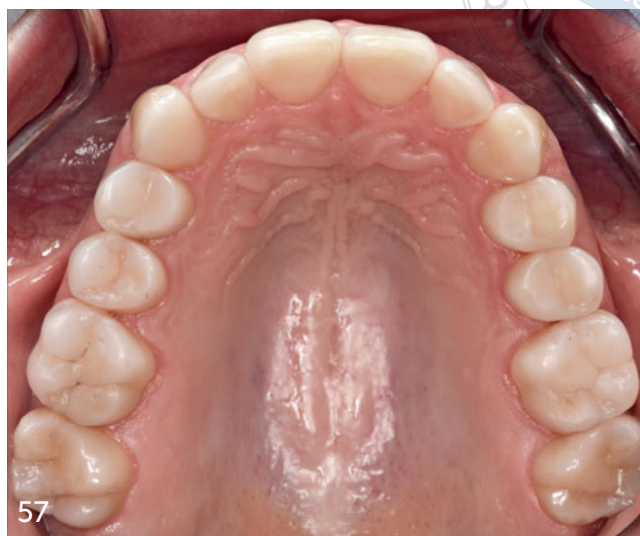


Figs 50 to 52 Posttreatment views with and without occlusal marks, showing that uniform and balanced occlusal contacts were also obtained.

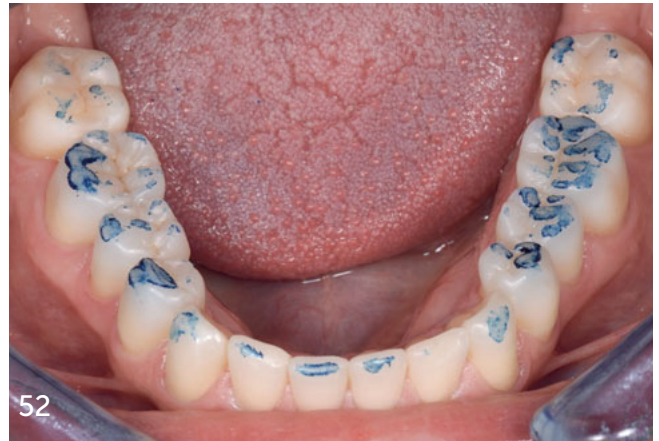
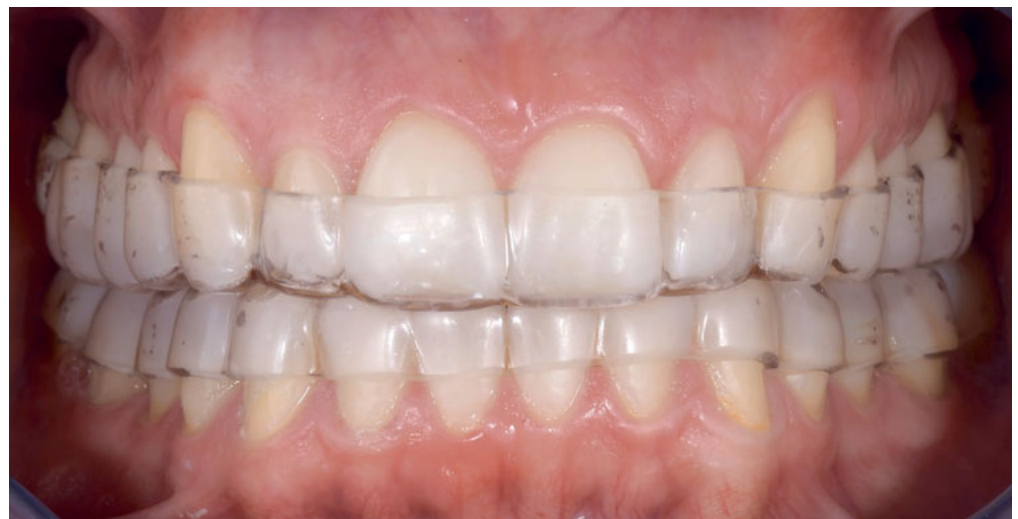
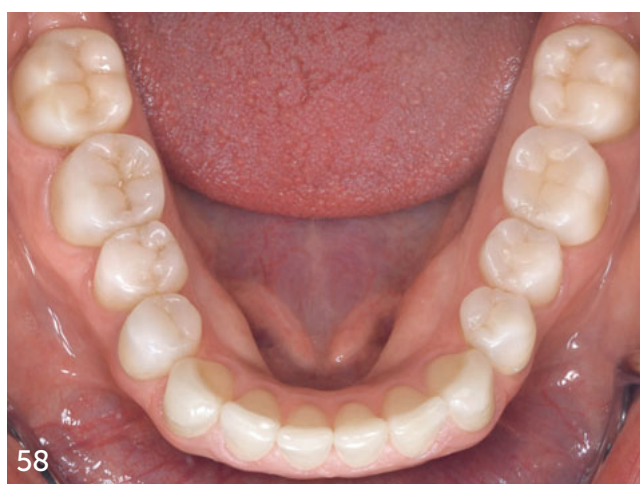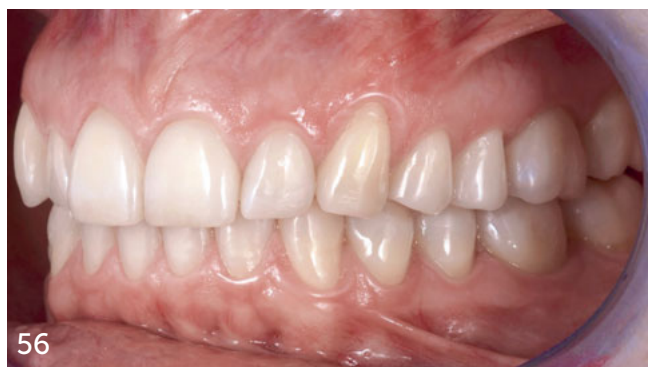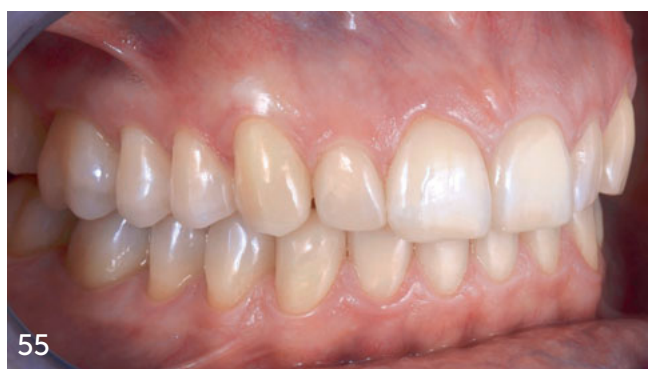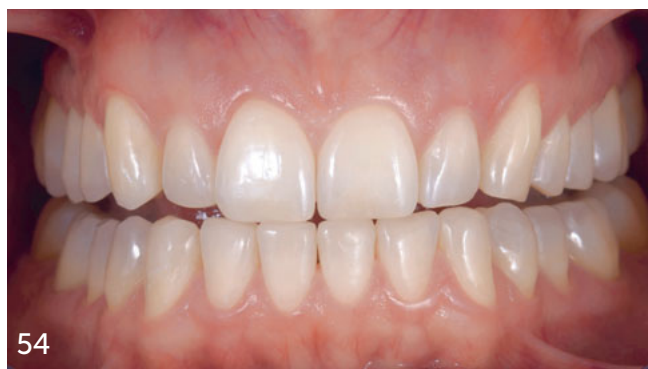Fig 53 The orthodontic correction stability and protection of the new composite restorations was guaranteed by rigid, heat-formed, 1.5-mm-thick maxillary and mandibular night guards.

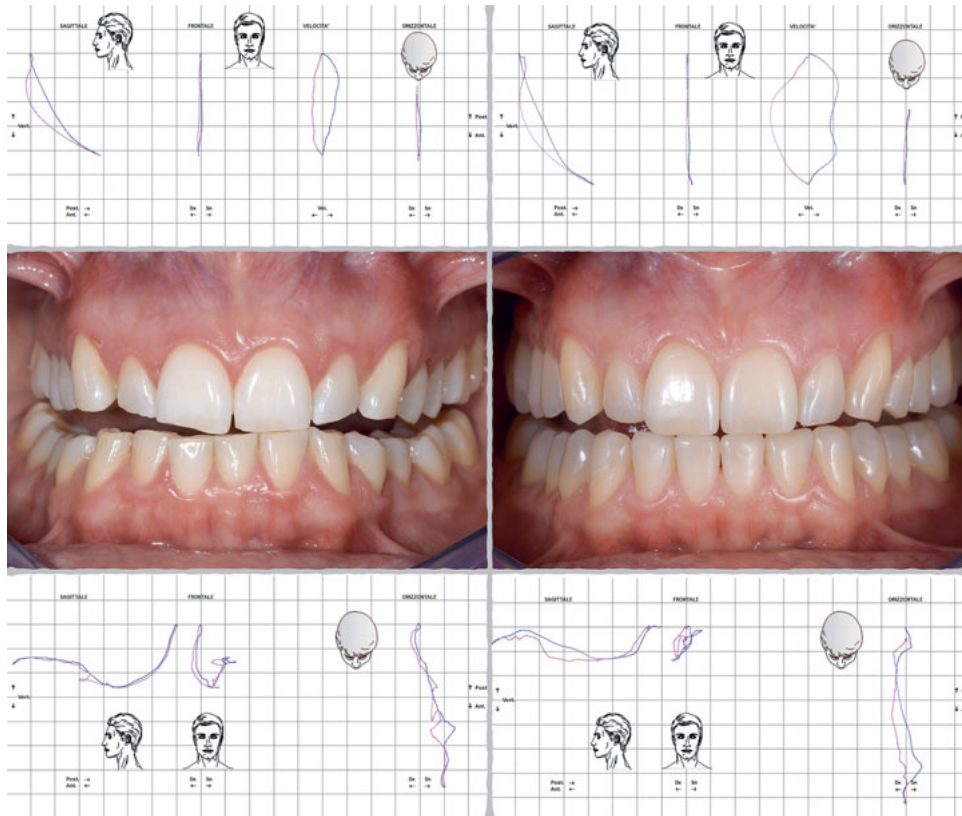




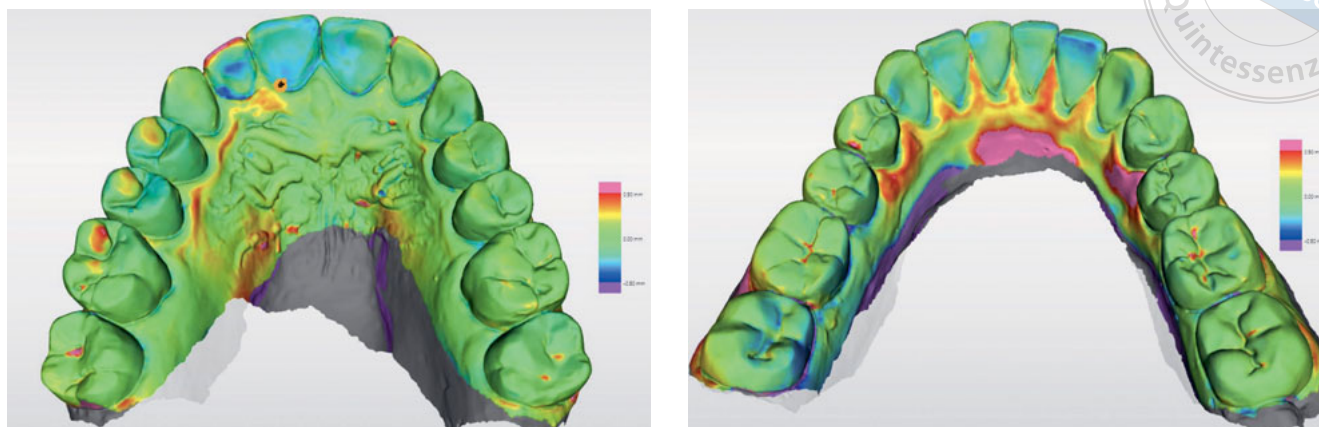
Figs 54 to 58 1-year posttreatment views demonstrating the occlusal, mechanical, and esthetic stability of the composite restorations.

Functional assessments were also documented and reported. Kinesiographic analysis was performed before and after treatment, showing modifications in the patients' pattern of movement after the full-mouth rehabilitation (Figs 59 and 60). Moreover, the anatomical stability obtained with the composite resin material was assessed using 3D comparison software (OraCheck 5.0; Dentsply Sirona), which visualizes, documents, and communicates changes in the

specific patient's intraoral situation (Figs 61 and 62) by superimposing posttreatment and 1-year follow-up. The overall occlusal anatomy did not show significant changes, apart from a minor loss of composite volume (0.2. to 0.4 mm) on the palatal side of the canine, and buccal cusps of the premolars and molars in quadrant 1, related to the right lateral guidance. A second case, treated with the same protocol, is presented with a 3-year follow-up (Figs 63 to 72).



Figs 59 and 60 Kinesiographic evaluation of different movements (open/close, protrusion, and left and right laterotrusion) with the illustration showing the three planes: sagittal, frontal, and horizontal. The analysis performed before and after the treatment is compared. The images also show anterior and lateral guidance before and after treatment.



Figs 61 and 62 3D analysis documenting the general stability of the rehabilitation performed with direct composite restorations after 1 year. Note a few wear points on the maxillary right quadrant due to predominant excursive movements on this side.

Discussion

An instrumental clinical aspect of the technique described in this article is the persistence of some anatomical references that allow the molding tray to be repositioned precisely in the mouth without a significant risk of deformation of the molded surfaces. Provided this condition is met, the technique can be said to be simple, effective, and reliable, involving relatively little chair time, which is of paramount importance for the acceptance of the method.

As for the various protocols involving chairside use of light-curing composites, the technical limitations of the full molding technique lie in the amount of tissue to be replaced and the mechanical performance of the material in cases of severe parafunctions (especially clenching). In fact, one condition for success relates to the magnitude of functional stresses and the thickness of the restorations; for instance, severe clenching with a limited VDO opening is logically more likely to induce composite failures such as material chipping, wear, and marginal degradation. Such failures are, however, considered 'minor' and usually necessitate only a repair procedure. Owing to the simplicity of the treatment and restor-

ation maintenance, the use of no-prep partial direct restorations appears to have irrefutable advantages and promising outcomes in the interceptive treatment of moderate abrasion and erosion.¹³⁻¹⁵ The alternative to the relatively simple direct composite option is to use pressed ceramics or CAD/CAM composite and ceramic restorations on the most critical teeth (usually mandibular molars) or for the full rehabilitation, mainly in cases where the extent of tooth wear is more severe.^{11,12,24,25} The known shortcomings of CAD/CAM and indirect methods are the need for substantial tooth preparation and increased treatment costs. Moreover, more invasive techniques such as crowns can lead to more dramatic failure patterns, as observed in conventional prosthetics over a long period of time.¹⁵ Therefore, partial indirect restorations (ie, onlays and overlays) are usually preferred, provided the individual tooth biomechanical status allows it (an exception is visible, severely discolored non-vital teeth). In any case, all parameters (wear amount, esthetics, function, immediate and long-term treatment costs) have to be carefully weighted to make the best decision for the patient.^{13-15,24,25}

A final important factor is patient compliance, which has a major impact on restor-

ation longevity and maintenance, especially in cases of parafunctions, and in particular sleep bruxism. Since it is difficult to ascertain the level of long-term compliance with a night guard, the direct composite option then presents an additional benefit during an 'observational' treatment phase. Knowing that composite restorations, even under high functional stresses, have the potential to last several years without major failure, the dental team can gain crucial information about the balance between risk factors and patient compliance, having at hand objective elements to eventually propose another treatment approach after a stabilization period of tooth wear.

Kinesiography analysis was performed before and after the restorative treatment (Figs 59 and 60). This 3D tracking of the jaw movements allowed for the monitoring of mandibular movements at the interincisal point, with the aim of providing a qualitative and quantifiable analysis of the patient's masticatory function and jaw movement patterns following the treatment. It is of interest to assess the impact of any occlusal therapy on the masticatory function of patients with known occlusal disorders.²⁶ When looking at the maximum opening and closing movements after a VDO augmentation, an overall increase of 1 cm was noticed (raising from 4.2 to 5.2 cm). Protrusive movements only increased slightly (from 3.3 to 3.6 cm) but showed a somewhat straighter pattern following treatment. Lateral excursive movements also increased slightly on the right side (from 1.4 to 1.6 mm), while remaining unaltered on the left; however, lateral movement patterns also appeared more symmetrical after treatment on the frontal plane, while being slightly more asymmetrical on the horizontal one. Overall, the patient rapidly adapted to the new jaw position after the VDO augmentation and did not show or complain about any lack of masticatory restriction, orofacial pain, or TMJ disturbance.

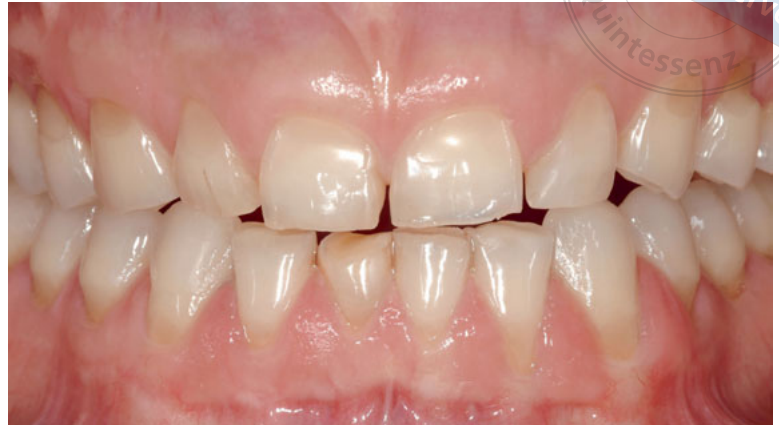
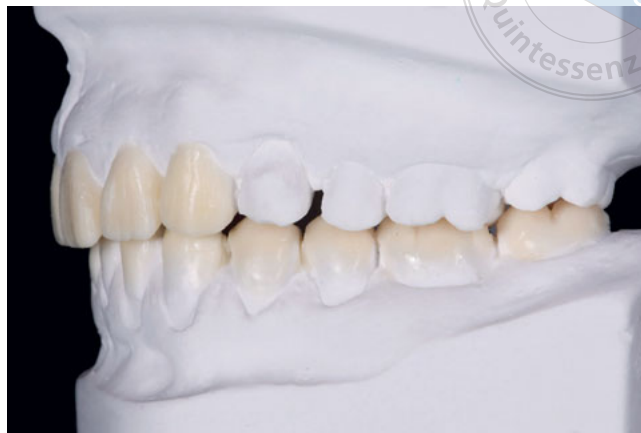
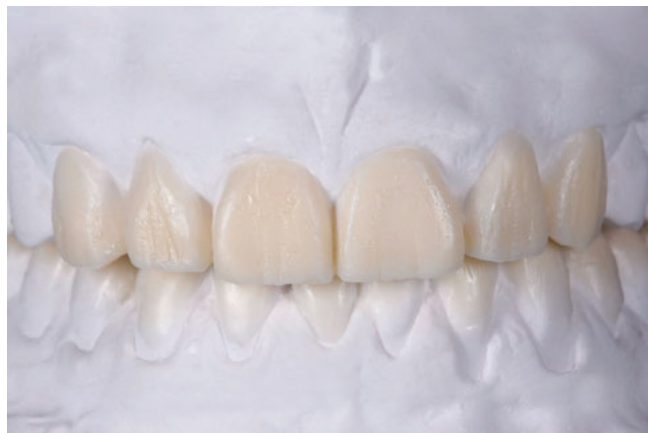Fig 63 Initial view of a 41-year-old female patient showing moderate to advanced tooth wear due to combined erosion and parafunction pathology.

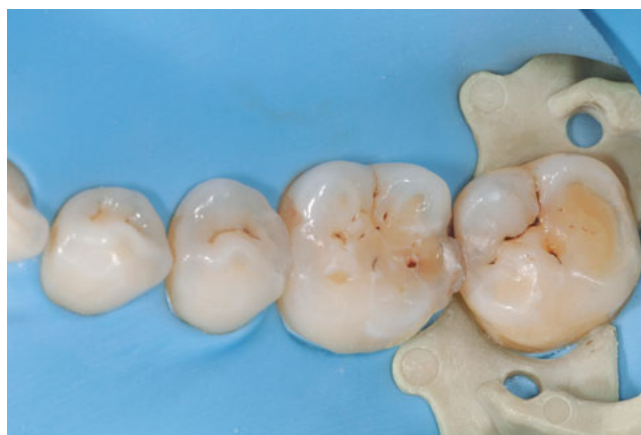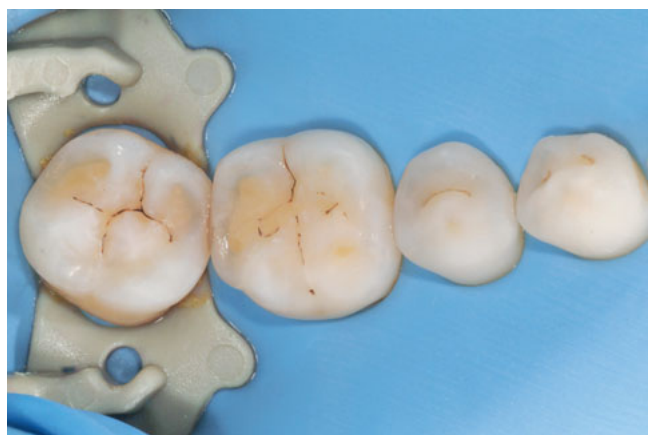Conclusion

This article presents a revised protocol for the full molding of occlusal surfaces that alleviates most of the difficulties experienced with other full or single molding techniques. Known limitations of molding techniques are the time-consuming removal of excesses and the possible inaccuracy of the restoration anatomy and function. Moreover, while an increase of the VDO is instrumental for treating tooth wear, using composite is practically the only option for a no-prep approach. This fact justified an improvement of molding protocols.

The technique presented here has significant potential to widen the acceptance of the direct approach in the context of an 'interceptive' treatment of tooth wear. There is an imperative requirement to reduce complex rehabilitations applied to severe tooth wear cases as result of delayed interventions due to their biomechanical and financial costs. This case reports also suggests a potential improvement of dynamic occlusion and function resulting from this method, a benefit which was previously only correlated to classical prosthetic rehabilitations.



Figs 64 and 65 The treatment approach, as per this diagnostic wax-up, was to augment the VDO using a full molding technique on the mandibular posterior teeth only. To this end, the same technique (previously described) was applied. For the mandibular and maxillary anterior teeth, a direct approach was also used with the help of indexes to restore esthetics and function, as defined by the wax-up.



Figs 66 and 67 Occlusal views of the pretreatment situation.

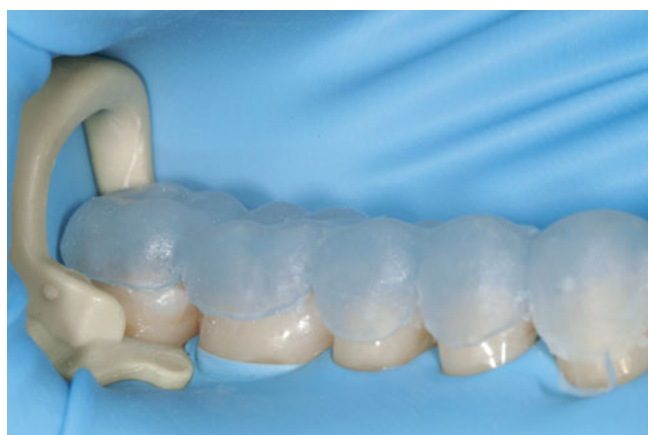
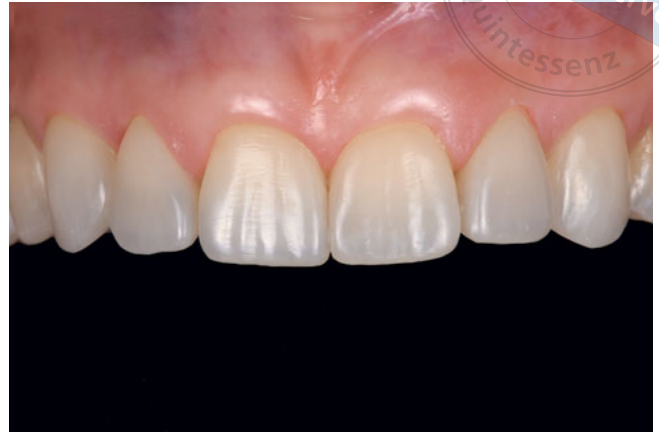
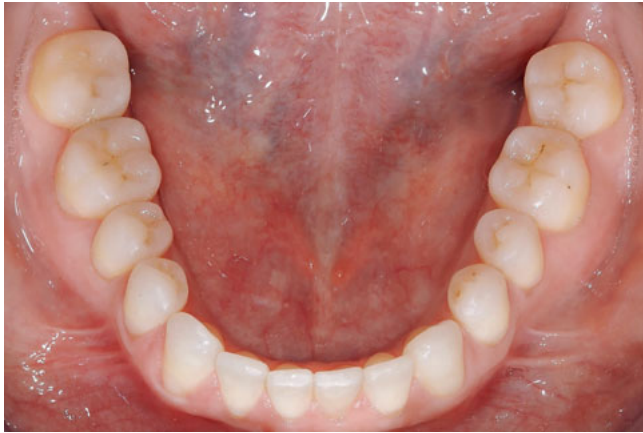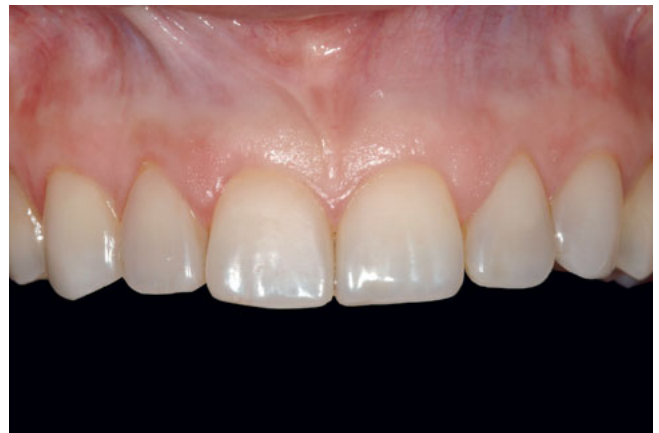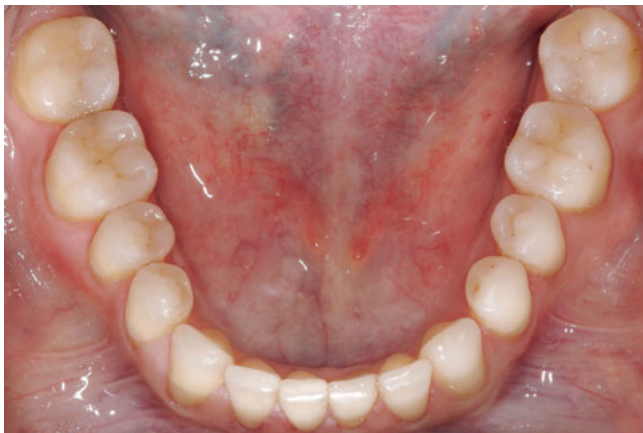Fig 68 Trial of the molding tray. Note again that tray embrasures were well opened to allow for the removal of composite excesses.



Figs 69 and 70 Posttreatment occlusal and anterior views showing the new occlusal anatomy and increased VDO as well as the new smile line and improved forms of the anterior teeth following a direct freehand approach.



Figs 71 and 72 3-year views of the smile and mandibular occlusion, demonstrating the satisfactory behavior of the no-prep direct composite restorations that were used in this case to reverse and stabilize the effects of the pathology.

Acknowledgment

The authors thank Mr Serge Erpen of Oral-Pro, Geneva, for the fabrication of the wax-up, setup, and trays shown in Figs 8 to 16.

References

1. Van't Spijker A, Rodriguez JM, Kreulen CM, Bronkhorst EM, Bartlett DW, Creugers NH. Prevalence of tooth wear in adults. *Int J Prosthodont* 2009;22:35–42.
2. Salas MMS, Nascimento GG, Huysmans MC, Demarco FF. Estimated prevalence of erosive tooth wear in permanent teeth of children and adolescents: An epidemiological systematic review and meta-regression analysis. *J Dent* 2015;43:42–50.
3. Van't Spijker A, Kreulen CM, Bronkhorst EM, Creugers NHJ. Occlusal wear and occlusal condition in a convenience sample of young adults. *J Dent* 2015;43:72–77.
4. Bartlett DW, Fares J, Shirodaria S, Chiu K, Ahmad N, Sherriff M. The association of tooth wear, diet and dietary habits in adults aged 18–30 years old. *J Dent* 2011;39:811–816.
5. Bardsley PF. The evolution of tooth wear indices. *Clin Oral Investig* 2008;12(suppl 1):S15–S19.
6. Lussi A, Jaeggi T, Zero D. The role of diet in the aetiology of dental erosion. *Caries Res* 2004;38(suppl 1):S34–S44.
7. Lussi A, Hellwig E, Zero D, Jaeggi T. Erosive tooth wear: diagnosis, risk factors and prevention. *Am J Dent* 2006;19:319–325.
8. Lussi A, Jaeggi T. Erosion – diagnosis and risk factors. *Clin Oral Investig* 2008;12(suppl 1):S5–S13.
9. Lavigne GJ, Khoury S, Abe S, Yamaguchi T, Raphael K. Bruxism physiology and pathology: an overview for clinicians. *J Oral Rehabil* 2008;35:476–494.
10. Lavigne GJ, Kato T, Kolta A, Sessle BJ. Neurobiological mechanisms involved in sleep bruxism. *Crit Rev Oral Biol Med* 2003;14:30–46.
11. Loomans B, Opdam N, Attin T, et al. Severe Tooth Wear: European Consensus Statement on Management Guidelines. *J Adhes Dent* 2017;19:111–119.
12. Carvalho TS, Colon P, Ganss C, et al. Consensus report of the European Federation of Conservative Dentistry: erosive tooth wear – diagnosis and management. *Clin Oral Investig* 2015;19:1557–1561.
13. Mesko ME, Sarkis-Onofre R, Cenci MS, Opdam NJ, Loomans B, Pereira-Cenci T. Rehabilitation of severely worn teeth: A systematic review. *J Dent* 2016;48:9–15.
14. Gulamali AB, Hemmings KW, Tredwin CJ, Petrie A. Survival analysis of composite Dahl restorations provided to manage localised anterior tooth wear (ten year follow-up). *Br Dent J* 2011;211:E9.
15. Smales RJ, Berekally TL. Long-term survival of direct and indirect restorations placed for the treatment of advanced tooth wear. *Eur J Prosthodont Restor Dent* 2007;15:2–6.
16. Ibsen RL, Ouellet DF. Restoring the worn dentition. *J Esthet Dent* 1992;4:96–101.
17. Christensen GJ. A new technique for restoration of worn anterior teeth – 1995. *J Am Dent Assoc* 1995;126:1543–1546.
18. Schmidlin PR, Filli T, Imfeld C, Tepper S, Attin T. Three-year evaluation of posterior vertical bite reconstruction using direct resin composite – a case series. *Oper Dent* 2009;34:102–108.
19. Ammannato R, Ferraris F, Marchesi G. The “index technique” in worn dentition: a new and conservative approach. *Int J Esthet Dent* 2015;10:68–99.
20. Ammannato R, Rondoni D, Ferraris F. Update on the ‘index technique’ in worn dentition: a no-prep restorative approach with a digital workflow. *Int J Esthet Dent* 2018;13:516–537.
21. Wazani BE, Dodd MN, Milosevic A. The signs and symptoms of tooth wear in a referred group of patients. *Br Dent J* 2012;213:E10.
22. Abduo J. Safety of increasing vertical dimension of occlusion: a systematic review. *Quintessence Int* 2012;43:369–380.
23. Abduo J, Lyons K. Clinical considerations for increasing occlusal vertical dimension: a review. *Aust Dent J* 2012;57:2–10.
24. Dietschi D, Argente A. A comprehensive and conservative approach for the restoration of abrasion and erosion. Part I: concepts and clinical rationale for early intervention using adhesive techniques. *Eur J Esthet Dent* 2011;6:20–33.
25. Dietschi D, Argente A. A comprehensive and conservative approach for the restoration of abrasion and erosion. Part II: clinical procedures and case report. *Eur J Esthet Dent* 2011;6:142–159.
26. Flores-Orozco EI, Rovira-Lastra B, Willaert E, Paire M, Martinez-Gomis J. Relationship between jaw movement and masticatory performance in adults with natural dentition. *Acta Odontol Scand* 2016;74:103–107.